



2021  
대한정위기능신경외과학회  
제26차  
정기 학술대회

New Era of Korean Stereotactic and Functional Neurosurgery

일시: 2021년 9월 4일(토) 07:30-17:00

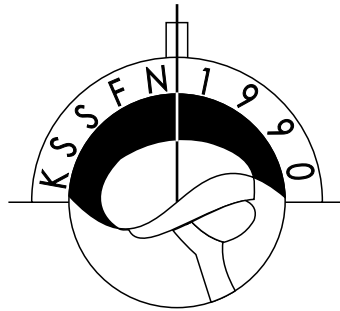
장소: 부산 누리마루 APEC하우스 2층 회의실



주최: 대한정위기능신경외과학회  
주관: 대한신경외과학연구재단

2021  
대한정위기능신경외과학회  
제26차  
정기 학술대회

New Era of Korean Stereotactic and Functional Neurosurgery

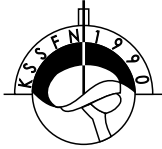


일시: 2021년 9월 4일(토) 07:30-17:00

장소: 부산 누리마루 APEC하우스 2층 회의실

주최: 대한정위기능신경외과학회

주관: 대한신경외과학연구재단



# 제26대 대한정위기능신경외과학회 임원명단


2020. 4. 1 - 2021. 9. 4

회장	김전	무상	성용	인제대
부회장	이	태	규	울산대
총무	손	병	철	가톨릭대
학술	김	은	영	가톨릭대
재무	정	현	호	가천대
기획	김	인	영	연세대
수련교육	박	용	숙	전남대
간행	김	중	현	중앙대
보험1	정	문	영	고려대
보험2	조	철	범	순천향대
홍보1	최	진	규	가톨릭대
홍보2	박	성	현	가톨릭대
진료심의	이	명	기	경북대
법제윤리	고	은	정	온종합병원
회칙개정	홍	석	호	전북대
국제교류	김	진	경	울산대
대외협력	한	성	록	경찰병원
회원관리	김	해	유	인제대
전산정보	나	영	철	인제대
교과서편찬	장	원	석	가톨릭관동대
학회사편찬	박	영	석	연세대
정책	이	원	희	충북대
WSSFN준비	박	균	제	인제대
고문번호사	이	상	훈	법무법인충정
특별	김	중	규	봉생병원
특별	황	형	식	조선대
특별	조	경	래	한림대
분과위원(방사선수술)	하	상	우	건국대
분과위원(뇌전증)	정	나	영	조선대
분과위원(운동질환)	최	혁	재	울산대
분과위원(통증)	박	창	규	한림대
분과위원(MVD)	김	주	평	경희대
분과위원(세포치료)	이	재	민	차의대
분과위원(IOM)	박	혜	란	부산대
분과위원(치매, 정신질환)	김	영	구	순천향대
분과위원(기초연구)	김	덕	령	이화여대
감사(2년차)	이	은	정	을지대
감사(1년차)	이	민	호	서울대
간사(총무)	이	승	훈	가톨릭대
간사(학술)	이	광	현	성균관대
간사(홍보)	박	지	희	충남대
간사(보험)				한림대
간사(기획)				가천대

# 인 사 말

존경하는 대한정위기능신경외과학회 회원 여러분!

1990년 2월 23일 정상섭 초대회장님께서 창립하시고 역대 회장님들과 장진우 세계정위기능신경외과학회 회장님, 여러 선배님들의 헌신적인 노력으로 2020년부터 시작된 코로나19와의 전쟁속에 유난히 어려웠던 환경속에도 여러 회원 여러분의 열성과 노력으로 30여년의 역사를 가지고 세계학회를 선도하는 학회로 많은 발전을 하였습니다.



2020년 작년 코로나19속에 아시아 오세아니언 정위기능신경외과학회를 정상섭 명예회장님, 장진우 세계정위기능신경외과학회 회장님, 이정일 회장님, 허룡 학술위원장님, 여러 회원님들의 도움으로 천년고도 경주에서 성공적으로 개최하였습니다. 정위기능신경외과는 운동성장애, 뇌전증, 통증, 방사선수술, 치매, 뇌신경기능장애, 난치성 정신질환 수술, 수술중 신경감시, 초음파를 이용한 뇌수술, 줄기세포치료, CT가 내장된 무틀감마나이프인 아이콘의 발전으로 큰 용적의 뇌종양이나 전이성 뇌종양에서 치료 환자가 급증하고 전이성 뇌종양의 치료는 감마나이프로 되어가고 있고 뇌와 컴퓨터간 인터페이스, 인공지능, 로봇의 발전은 Neuroscience의 미개척분야를 더욱 발전시키고 있습니다.

지난 1년 6개월동안 학회재정을 올리기 위하여 홈페이지 배너광고수입을 증대하였으며, 향후 학회지가 대한의학회 인증, SCI 진입에 도움이 되길 바라며, 현재 김우경 이사장님, 보험이사님의 많은 도움으로 수술중 신경감시 보험수가 문제가 해결되길 바라며 2022년 9월 4-7일 인천송도에서 개최되는 세계학회의 성공적인 개최를 위해 노력을 경주해야 합니다.

이번 제26차 학술대회는 세계적인 휴양지인 해운대 동백섬의 누리마루에서 off line 대면학회를 국내 연자 중심으로 개최합니다.

백신을 맞고 태평양의 시원한 바닷바람이 부는 해운대 동백섬에서 화합된 학회가 될 수 있도록 많은 협조 부탁드립니다.

여러 회원님들의 건승을 기원합니다.

감사드립니다.

2021년 9월 4일

대한정위기능신경외과학회 회장 김 무 성



# 2021 대한정위기능신경외과학회 제26회 정기 학술대회

일시: 2021년 9월 4일(토) 07:30-17:00

장소: 부산 누리마루 APEC하우스 2층 회의실

07:30-08:00 등 록  
08:00-08:10 개회사  
축 사  
격려사

대한정위기능신경외과학회 회장 김무성  
대한신경외과학회 회장 이일우  
세계정위기능신경외과학회 회장 장진우

08:10-08:50	<b>Scientific Session I: Movement Disorders</b>	좌장: 인제대 김무성, 가톨릭대 허 룡
	MD-1. Vacuum-Assisted Closure with Temporalis Muscle Reconstruction for Recurrent Scalp Erosion Following Deep Brain Stimulation .....	충북대 박영석 1
	MD-2. Hippocampal Volume is Related to Olfactory Impairment in Parkinson's Disease .....	고려대 노해원 2
	MD-3. Reversible Hyperkinesia of Rat Induced by Optogenetic Stimulation of Parafascicular Nucleus .....	순천향대 정문영 3
08:50-09:50	<b>Special Lecture: Basic Medical Neuroscience</b>	좌장: 가톨릭대 손병철, 가톨릭대 이태규
	1. Basic research: The Cargo-transport and Disease of Molecular Motor Protein, Kinesin .....	인제대 생화학교실 석대현 6
	2. Regulation of Dynein Motor Protein by NAGK: Its Application for Neuronal Health .....	동국대 해부학교실 문일수 8
09:50-10:10	<b>Coffee Break</b>	
10:10-11:00	<b>Symposium I: 부울경 정위기능 심포지엄 - Institutional Experience of Stereotactic and Functional Neurosurgery</b>	좌장: 온종합병원 이명기, 봉생병원 이상훈
	1. Inje Univ. Haeundae Paek Hospital .....	인제대 김해유 10
	2. Pusan National Univ. Hospital .....	부산대 이재민 12
	3. Ulsan Univ. Hospital .....	울산대 정나영 14
11:00-11:40	<b>Scientific Session II: Radiosurgery</b>	좌장: 전북대 최하영, 성균관대 이정일
	R-1. 상부경추부 종양에 대한 감마나이프 방사선수술의 임상적 분석 .....	인제대 한승주 15
	R-2. Effectiveness of Gamma Knife Thalamotomy for Essential Tremor .....	성균관대 최혜원 16
	R-3. Can Trigeminal Schwannoma-related Symptoms be Controlled with Gamma Knife Radiosurgery? .....	경희대 박창규 17
	R-4. Gamma Knife Radiosurgery for the Spontaneous Carotid-Cavernous Fistulas: Preliminary Report .....	전북대 고은정 18

11:40-12:10 정기총회 및 단체사진

12:10-13:10 점심식사

13:10-13:50 **Scientific Session III: Epilepsy/Cranial Rhizopathy** 좌장: 아주대 안영환, 울산대 홍석호

- EC-1. Usefulness of Three-dimensional Image Reconstruction in Identification of Neurovascular Relationships for Microvascular Decompression ..... 가톨릭대 **이창익** 19
- EC-2. Re-appearance of Lateral Spread Response after Successful Microvascular Decompression in Patients with Hemifacial Spasm ..... 울산대 **김민수** 20
- EC-3. Involvement of the Vertebral Artery in Hemifacial Spasm: Clinical Features and Surgical Strategy ..... 성균관대 **권혁준** 21
- EC-4. Pitfalls in SEEG Surgery ..... 연세대 **박소희** 22

13:50-14:40 **Symposium II: Early Experience as a Young Functional Neurosurgeon** 좌장: 연세대 장원석, 인제대 한성록

- 1. Sacral Neuromodulation ..... 가톨릭대 **최진규** 24
- 2. Intrathecal Baclofen for the Treatment of Spasticity ..... 이화여대 **김영구** 27
- 3. Neuromodulation for Intractable Headaches ..... 건국대 **조경래** 29
- 11:45-12:00 4. 젊은 정위기능신경외과 의사의 기초연구 수주 및 셋업 ..... 가톨릭관동대 **나영철** 31

14:40-15:00 Coffee Break

15:00-15:40 **Symposium III: Integration of Functional Neurosurgery and Recent Technology** 좌장: 울산대 전상용, 인제대 김해유

- 1. Machine Learning in Intraoperative Monitoring ..... 울산대 **김민수** 34
- 2. Application of Stereotactic Surgical Robot Systems in Neurosurgery ..... 성균관대 **이승훈** 36

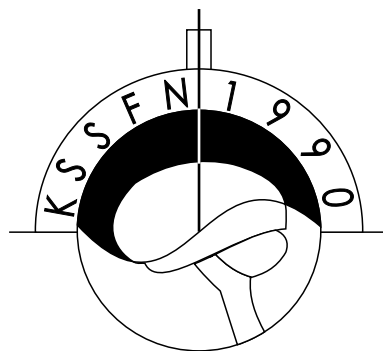
15:40-16:20 **Scientific Session IV: Pain/Others** 좌장: 가천대 김은영, 고려대 김종현

- PO-1. Percutaneous Balloon Compression of the Trigeminal Ganglion in Post-herpetic Trigeminal Neuralgia: Outcome in Case Series of 8 Patients ..... 온종합병원 **이명기** 37
- PO-2. Which stimulation Mode is Most Effective for Postplegic Neuropathic Pain in a Patient with Combined Vc DBS and Cervical SCS ..... 충북대 **김동욱** 38
- PO-3. Compulsive Cuts of Neurosurgical Labor Fee in MVD Surgery ..... 아주대 **안영환** 39
- PO-4. Stereotactic Surgery using the Kymero Stereotactic Robotic Device ..... 연세대 **장경원** 40

An Investigation of Thalamic Nuclei Volumes and the Intrinsic Thalamic Structural Network Based on Motor Subtype in Drug Naive Patients with Parkinson's Disease ..... 인제대 김해유 41

16:30-16:40 **우수연제상 시상**

16:40- **폐회사** 대한정위기능신경외과학회 회장 김무성

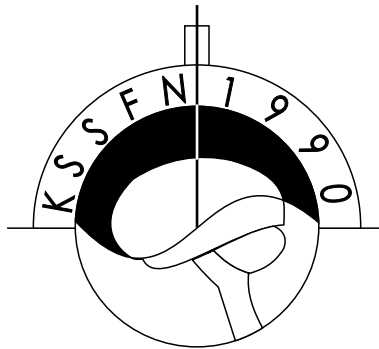


---

## Poster Presentation

---

P-1. The Effect of Acute Exposure to RFR on Iba1-positive Microglia in Neonatal Rat Brain .....	아주대 김혜선	42
P-2. Focused Ultrasound Mediated Temozolomid Delivery Into Intact Blood-brain Barrier Tissue Improves Survival of Patient Derived Xenograft Rat Model of Glioblastoma .....	연세대 장원석	43
P-3. Brain-Machine Interface Based Analysis of Neural Signals in Somatosensory Cortex with Virtual Reward .....	연세대 김태준	45



---

# Scientific Session I

## Movement Disorder

---

좌장: 인제대 김무성, 가톨릭대 허 룡

# MD-1. Vacuum-Assisted Closure with Temporalis Muscle Reconstruction for Recurrent Scalp Erosion Following Deep Brain Stimulation

**Dong Wook Kim, Ye Ryung Im, Aryun Kim, Young Seok Park**

*Department of Neurosurgery, Chungbuk National University College of Medicine, Cheongju, Korea*

**Objective:** Scalp erosion is not an uncommon complication of deep brain stimulation (DBS) surgery. Although various methods have been proposed to prevent and manage complications, there are still challenges. We introduce a case of recurrent scalp erosion after DBS surgery treated with vacuum-assisted closure.

**Case description:** This article reports the case of a patient who underwent DBS for advanced Parkinson's disease and suffered from recurrent scalp erosion with device extrusion through the skin. Scalp erosion occurred 2 years after DBS and repeated improvement and deterioration despite scalp reconstruction using a skin flap. We opened the wound and performed temporal muscle reconstruction to cover the burr hole site, and we changed the exposed cable and applied vacuum-assisted closure. During the follow-up period, no signs of erosion or infection occurred, and DBS efficacy was preserved.

**Conclusion:** To date, the available management strategies for scalp erosion after DBS are revision with debridement and scalp reconstruction using skin flaps or skin grafts. However, if erosion occurs repeatedly despite the above management strategies, vacuum-assisted closure with temporalis muscle reconstruction could be a suitable option. We suggest that if the condition of the scalp is weakened, it is worth considering this approach preferentially.

**Key Words:** DBS; scalp erosion; vacuum-assisted closure.

MEMO



## MD-2. Hippocampal Volume is Related to Olfactory Impairment in Parkinson's Disease

**Haewon Roh<sup>1</sup>, June Kang<sup>2</sup>, Seong-Beom Koh<sup>3</sup>, Jong Hyun Kim<sup>1</sup>**

<sup>1</sup>*Department of Neurosurgery, Guro Hospital, Korea University Medical Center, Seoul;*

<sup>2</sup>*Department of Brain and Cognitive Engineering, Korea University, Seoul;*

<sup>3</sup>*Department of Neurology, Guro Hospital, Korea University Medical Center, Seoul, Korea*

**Objective:** Recent evidence has suggested that hyposmia in patients with Parkinson's disease (PD) may be due to impaired central processing. Furthermore, the hippocampus has been regarded as a critical structure linking olfactory impairment and cognitive impairment in PD patients. This study aimed to identify significant structural alterations of the the hippocampus in PD patients with hyposmia, and to determine whether these structural changes are significantly associated with olfactory impairment severity.

**Methods:** Eighteen idiopathic PD patients with hyposmia and 18 age- and sex-matched PD patients without hyposmia were enrolled. Hippocampal volume and its subfields were measured using FreeSurfer software and compared between hyposmic and normosmic PD patients. We also compared hippocampal substructures' volumes and correlated the hippocampal volumes with hyposmia severity.

**Results:** PD patients with hyposmia had significantly smaller hippocampal volumes. Among the three components of the hippocampus, the hippocampal body showed a markedly lower volume, which correlated significantly with the cross-cultural smell identification test score that represents olfactory function status. Hippocampal subfield analysis showed that substructures (subiculum, molecular layer) that constitute the hippocampal body showed the most significant volume difference.

**Conclusions:** We suggest that atrophy of the bilateral hippocampus implies underlying problems in the central olfaction process in PD patients. In particular, the hippocampus might not only play a critical role in olfaction but could also be important for elucidating possible mechanisms of broad non-motor symptoms in PD patients.

**Key Words:** Cognition, Hippocampus, Hyposmia, Olfactory, Parkinson's disease



## MD-3. Reversible Hyperkinesia of Rat Induced by Optogenetic Stimulation of Parafascicular Nucleus

**Moonyoung Chung<sup>1</sup>, Young Seok Park<sup>2</sup>**

<sup>1</sup>*Department of Neurosurgery, Soonchunhyang University College of Medicine, Bucheon Hospital, Bucheon;*

<sup>2</sup>*Department of Neurosurgery, Chungbuk National University College of Medicine, Cheongju, Korea*

Dyskinesia is a neurological disorder characterized by involuntary hyperkinesia due to the abnormal function of the basal ganglia, and the basal ganglia circuit is the target of treatment for this disease. The parafascicular nucleus (PF) plays a pivotal role in controlling the basal ganglia, however how PF affects the development of dyskinesia remains unclear. Currently available animal models of dyskinesia have not been linked to clinical studies on the treatment of dyskinesia. This discordance may be because of the absence of an appropriate animal model suitable for the integrative aspect of dyskinesia. Thus this study aimed to develop an animal model of dyskinesia that can be reversibly controlled by stimulating the PF using optogenetics. Fourteen rats were underwent stereotactic operation by injecting the virus vector "AAV2-hSyn-ChR2-mCherry" to the lateral one-third of the PF. Baseline and post-stimulation behavioral tests were performed. Dyskinesias were found in seven rats. Dyskinesia scores after light stimulation significantly increased compared to those baseline. In rats with dyskinesia, it was confirmed that the mCherry protein was expressed in the PF, while the rats without dyskinesia did not present with the mCherry protein. Thus, dyskinesia could be reversibly induced when the PF was stimulated using an optogenetic method.

MEMO





---

# Special Lecture

## Basic Medical Neuroscience

---

좌장: 가톨릭대 **손병철**, 가톨릭대 **이태규**

## CURRICULUM VITAE

### 석 대 현

근무처: 인제대학교 의과대학 생화학교실 교수

E-mail: daehyun@inje.ac.kr

### 학력 사항

1988            경북대학교 의과대학 학사  
1991            일본 동경대학교 의과대학 석사  
1995            일본 동경대학교 의과대학 박사

### 연수 사항

1995-1997    호주 멜보른대학교 의과대학 생화학교실  
1997-2001    일본 동경대학교 의과대학 해부학교실

### 경력 사항

2001년-현재    인제대학교 의과대학 생화학교실 교수  
2018            한국생명과학회 학술위원장  
2020            한국생명과학회 운영위원장  
2006-2009    인제대학교 의과대학 학생부학장보  
2009-2015    인제대학교 의과대학 교무부학장보  
2019-2021    인제대학교 의과대학 국제교류부처장



## Basic Research: The Cargo-transport and Disease of Molecular Motor Protein, Kinesin

Dae-Hyun Seog<sup>1</sup>, Mooseog Kim<sup>2</sup>

<sup>1</sup>Departments of Biochemistry, <sup>2</sup>Neurosurgery, Inje University College of Medicine, Busan, Korea

The proper axonal transport is essential for the neuron survive. This axonal transport is mediated by microtubule-dependent molecular motor proteins, kinesin and cytoplasmic dynein which move their cargo along long microtubule tracks in neuron. Kinesins are ATP-dependent plus-end-directed motor proteins for the intracellular transport of organelles, vesicles, RNA complexes and protein complexes. The axonal cargo transport is modulated by adaptor proteins, which link the kinesin to their cargo. Mislocalization of these different cargos has been linked to neuron dysfunction and degeneration. Recently, several studies have revealed the relationship between kinesins and disease. Furthermore, advances in molecular genetics in mice and humans have revealed that kinesins-mediated axonal transport is relevant to various neurological disorders such as Huntington disease, Spastic paraplegia SPG10, and Charcot-Marie-Tooth disease (CMT). Here, we will present and discuss the several important physiological roles of kinesins in mammals and certain human disease.

**Key Words:** Adaptor protein, Cargos, Genetic disease, Kinesin, Neuron

MEMO



## CURRICULUM VITAE

### 문 일 수

근무처: 동국대학교 의과대학 해부학교실 교수

E-mail: moonis@dongguk.ac.kr

### 학력 사항

- 1981 경북대학교 의과대학 학사
- 1983 서울대학교 대학원 석사
- 1991 University of New Brunswick, Canada 박사

### 연수 사항

- 1991-1994 California Institute of Technology
- 2015-2016 University of Connecticut
- 2008 일본 Shinshu University

### 경력 사항

- 1994-현재 동국대학교 의과대학 해부학교실 교수
- 2020 한국생명과학회 회장
- 2015-2016 동국대학교 의과대학 연구부학장



## BRegulation of Dynein Motor Protein by NAGK: Its Application for Neuronal Health

**Raju Dash, Diyah Fatimah Oktaviani, Ho Jin Choi, Ripon MKH, Binod Timalisina, Yeasmin Akter Munni, Sarmistha Mitra, Il Soo Moon**

*Department of Anatomy, Dongguk University College of Medicine, Gyeongju, Korea*

Cytoplasmic dynein 1 is the major molecular motor moving cargoes such as mitochondria, organelles and proteins towards the minus end of microtubules. Dynein is involved in multiple basic cellular functions, such as mitosis, autophagy, neuritogenesis, cellular movement and neurodegeneration such as Alzheimer's disease, Parkinson's disease, Huntington's disease and motor neuron diseases. The hallmark of neurodegenerative diseases (NDs) is accumulation of toxic protein. Therefore, NDs are proteinopathies, where defects of dynein-dependent processes such as autophagy or clearance of aggregation-prone proteins are found in most of these diseases. Despite numerous causes for the generation of disease-evoking proteins the removal system to maintain cellular protein quality control is relatively much simple. When the chaperone and proteasome systems are overwhelmed, the toxic proteins are transported by dynein to the cell center, where they aggregate to form large aggresomes which eventually are cleared by autophagy. Therefore, acceleration of dynein will promote autophagy to help clearance of toxic protein aggregations. Our laboratory found N-acetylglucosamine kinase (NAGK) promotes diverse dynein functions in normal and pathological conditions like NDs. In this talk the molecular mechanism for dynein activation by NAGK and its potential application in combating NDs will be discussed.

**Key Words:** Adaptor protein, Cargos, Genetic disease, Kinesin, Neuron

MEMO



---


# Symposium I

부울경 정위기능 심포지엄 - Institutional Experience  
of Stereotactic and Functional Neurosurgery

---

좌장: 온종합병원 **이명기**, 봉생병원 **이상훈**

**CURRICULUM VITAE**



**Hae Yu Kim, MD, PhD**

**ADDRESS:** Associate Professor, Department of Neurosurgery,  
Haeundae Paik Hospital, Inje University College of Medicine,  
Busan, Korea  
E-mail: hykim080356@gmail.com, hykim0803@naver.com

**EDUCATIONAL BACKGROUND:**

- 1994-2000 Bachelor of Medicine. College of Medicine, Keimyung University, Daegu, Korea
- 2000-2001 One-year Rotating Internship. Seoul Medical Center, Seoul, Korea
- 2001-2005 Four-year Residency. Department of Neurosurgery, Sanggyepaik Hospital, Inje University College of Medicine, Seoul, Korea
- 2003-2005 Graduate School, Inje University College of Medicine, Korea  
Master of Science in Medicine (Department of Neurosurgery)  
The thesis for master degree entitled "An analysis of factors and physical activities associated with intracranial aneurysmal rupture"
- 2011-2013. Graduate School, Inje University College of Medicine, Korea  
Doctor of Science in Medicine (Department of Neurosurgery)  
The thesis for doctor degree entitled "The regulatory role of VSIG4 expressed on tumor-associated macrophages in anti-tumor immunity"

**MEMBERSHIPS IN MEDICAL SOCIETIES:**

- Korean Medical Association
- Korean Neurosurgical Society
- Korean Society for Stereotactic & Functional Neurosurgery
- Korean Brain Tumor Society
- Korean Society of Neurooncology



## Inje University Haeundae Paek Hospital

**Hae Yu Kim, MD, PhD**

*Department of Neurosurgery, Haeundae Paik Hospital, Inje University College of Medicine,  
Busan, Korea*

MEMO





## CURRICULUM VITAE

### Jae Meen Lee, MD

**ADDRESS:** Assistant Professor, Department of Neurosurgery,  
Pusan National University College of Medicine, Busan, Korea

#### Academic Education

2006 MD. degree from Pusan National University College of Medicine, Busan, Korea  
2017 Master degree from Pusan National University College of Medicine, Busan, Korea

#### Professional Activities

2010-2014 Resident of Neurosurgery in Pusan National University Hospital, Busan, Korea  
2014-2015 Clinical Fellow in Pusan National University Hospital, Busan, Korea  
2015-2017 Clinical Fellow in Seoul National University Hospital, Seoul, Korea  
2017-present Assistant Professor in Pusan National University Hospital, Busan, Korea



# Pusan National University Hospital

**Jae Meen Lee, MD**

*Department of Neurosurgery, Pusan National University College of Medicine, Busan, Korea*

MEMO



## CURRICULUM VITAE

### Na Young Jung, MD, PhD

**Address:** Assistant Professor, Department of Neurosurgery, Ulsan University Hospital,  
University of Ulsan College of Medicine, Ulsan, Korea

#### Education:

2003-2008 Keimyung University College of Medicine  
2010-2012 MS, Keimyung University College of Medicine, Graduate School  
2015-2018 PhD, Keimyung University College of Medicine, Graduate School

#### Carrier:

2010-2014 Residency of Neurosurgery, Dongsan Medical Center, Keimyung University  
2014-2015 Clinical Fellow, Department of Neurosurgery, Dongsan Medical Center, Keimyung University  
2015-2018 Clinical fellow of Functional Neurosurgery, Department of Neurosurgery, Yonsei University,  
College of Medicine  
2019 Clinical Assistant Professor, Department of Neurosurgery, Ulsan University Hospital  
2020 Assistant Professor, Department of Neurosurgery, University of Ulsan College of Medicine,  
Academic Activity  
2014-present Member of Korean Neurosurgical Society



## Ulsan University Hospital

**Na Young Jung, MD, PhD**

*Department of Neurosurgery, Ulsan University Hospital, University of Ulsan College of Medicine,  
Ulsan, Korea*

MEMO



---

# Scientific Session II

## Radiosurgery

---

좌장: 전북대 **최하영**, 성균관대 **이정일**

## R-1. 상부경추부 종양에 대한 감마나이프 방사선수술의 임상적 분석

한 승 주

인제대학교 부산백병원 신경외과

**목적:** 대공, 상부경추부는 운동신경 및 혈관들이 위치하는 복잡한 영역이며, 과거 감마나이프 수술의 하한은 대공이었으나, 감마나이프 기계의 발전으로 상부경추부까지 치료가 가능해 졌으며, 감마나이프폐쇄손 등을 이용하여 상부경추부 종양을 치료하고 치료효과를 분석하였다.

**방법:** 1997년부터 2019년까지 부산백병원에 입원하여 경추부 종양으로 진단받은 26례의 환자를 대상으로 감마나이프 수술을 시행하였다. 남녀비는 4:22, 연령은 26-75세(평균 52.5세), 종양의 종류는 혈관모세포종 9, 수막종 9, 성상세포종 9, 신경초종 2, 혈관종 1, ependymoma 1, chondroid tumor 1 순이며 감마나이프 수술 전 6례에서 수술을 시행하였다. 감마나이프 수술 때 평균최대선량은 21.3 Gy, 평균주변부 선량은 10.6 Gy로 조사하였다.

**결과:** 평균추적기간은 평균 47.2개월(8-152개월)로 14례에서는 종양이 작아지고 12례에서는 안정적이며 치료 합병증은 없었다.

**결론:** 감마나이프수술은 경추 4번까지의 상부경추 수막종, 성상세포종, 혈관모세포종, ventral 대공주위 종양을 신경학적 장애 없이 치료할 수 있으며, 렉셀 G 프레임은 감마나이프폐쇄손이나 아이콘을 이용하여 효과적으로 종양을 치료할 수 있다.

MEMO



## **R-2. Effectiveness of Gamma Knife thalamotomy for essential tremor**

**Hye Won Choi, Jung-Il Lee**

*Department of Neurosurgery, Samsung Medical Center, Sungkyunkwan University School of Medicine, Seoul, Korea*

**Objective:** The purpose of this study was to describe the results following nucleus ventralis intermedius (VIM) Gamma Knife thalamotomy (GKT) for medically refractory essential tremor in a cohort of patients that were not eligible for surgical treatment.

**Methods:** Out of 20 patients who underwent GKT for disabling essential tremor after medical treatment, one underwent a bilateral staged VIM thalamotomy procedure. The rest were unilateral cases. All the patients had no evident success from medical treatment. Their mean age was 71.5 years. Most patients were elderly or had underlying medical diseases. A maximum dose of 130 Gy was administered to the VIM, using a single 4-mm isocenter. The Fahn-Tolosa -Marin clinical tremor rating scale was used twice - before and after radiosurgery - to evaluate the severity of tremor and ability to handwrite, draw, and pour water. The measurements were compared to assess any improvements in alleviating the essential tremor.

**Results:** There were 16 evaluable patients, with scores from both before and after the radiosurgery. The median follow-up period was 14 months. The mean action tremor score was  $3.13 \pm 0.62$  before GKT and  $2.38 \pm 1.09$  after radiosurgery ( $p=0.0205$ ). The mean writing score was  $2.75 \pm 1.00$  prior to GKT and  $2.19 \pm 0.98$  afterwards ( $p=0.0014$ ). The mean drawing score was  $2.88 \pm 1.20$  prior to GKT and  $2.13 \pm 1.36$  afterwards ( $p=0.0008$ ). The mean water-pouring score was  $2.69 \pm 1.20$  prior to GKT and  $1.94 \pm 1.34$  afterwards ( $p=0.0065$ ). Three patients (18.75%) exhibited improvements in all action tremor, writing, drawing, and water-pouring scores; eight (50.0%) in two or three different scores; four (25.0%) only in one score.

**Conclusions:** Given that many of the essential tremor patients are generally elderly, it is difficult to follow up over an extended period. During this study, four patients became deceased during the follow-up period. Based on the conventional life expectancy of the essential tremor patients and a relatively high prospects of substantial improvements following a GKT, GKT can be considered a less-invasive and effective treatment option for medically refractory essential tremor.



### R-3. Can trigeminal schwannoma-related symptoms be controlled with gamma knife radiosurgery?

Chang Kyu Park

*Department of Neurosurgery, Kyung Hee University Medical Center, Seoul, Korea*

**Objective:** The effectiveness of gamma knife radiosurgery (GKRS) for the management of trigeminal schwannomas (TS) has been established. Although GKRS has been shown to inhibit tumor growth, the effect of GKRS on the symptoms caused by TS has not been sufficiently studied. In this study, symptomatic changes following GKRS for the management of symptomatic TS were investigated using long-term follow-up results.

**Methods:** A retrospective analysis was performed on 32 patients with TS who underwent GKRS between May 1994 and December 2016. Clinical charts, radiographic results, and surgical records were reviewed. To evaluate whether symptoms improved after GKRS, patient demographics, GKRS profile, radiological tumor size change, and tumor location were analyzed.

**Results:** Tumor control after GKRS for symptomatic TS was 87%. The improvement rates for facial pain at 6, 12, and 24 months after GKRS were 46%, 72%, and 86%, respectively. For the same time intervals, facial paresthesia improved by 12%, 46%, and 52%, respectively. Of the patients with diplopia, 17 had improved symptoms 12 months after GKRS, and 50% of the patients improved after 24 months.

**Conclusion:** GKRS can be an effective treatment modality for TS tumor control and shows favorable results in improving TS-related symptom, especially facial pain.

**Key Words:** Trigeminal schwannoma, Facial pain, Facial paresthesia, Diplopia, Gamma knife radiosurgery

MEMO





## **R-4. Gamma Knife Radiosurgery for the Spontaneous Carotid-Cavernous Fistulas: Preliminary Report**

**Eun Jeong Koh, Ha-Young Choi, Jong-Myong Lee, Jung-Soo Park**

*Department of Neurosurgery, Jeonbuk National University Medical School Hospital, Jeonju, Korea*

**Objective:** Gamma knife radiosurgery (GKRS) is considered as an adjuvant treatment for carotid-cavernous fistulas (CCF) and many previous reports concluded that GKRS is a useful additional modality. We performed GKRS to CCF without any endovascular treatment and showed the preliminary results.

**Methods:** Between December 2017 and December 2020 we did ten GKRS to nine patients. Seven patients were female and two patients were male (mean 68,6 years old). Six fistulae were Barrow type B. Two fistulae were type C. One was type D. One was type A associated with car-accident. Gamma knife radiosurgery was performed with a marginal dose of 16 to 18Gy (50% isodose line) and the mean targeted volume was 0.96 cm<sup>3</sup> (0.13-3.05 cm<sup>3</sup>). The target point of the CCF was the fistula site for the type A and B and the compartment of the cavernous sinus for the type C and D.

**Results:** All fistulas responded favorably to the GKRS with an improvement of symptoms beginning after 1 to 8 weeks. The mean follow-up period is 19,6 months (7 to 43 months). Six fistulas were disappeared which was confirmed by trans-femoral angiography or orbit MRI and brain MRA. Four fistulas were decreased by more than 50%. There was no recurrence and no adverse effect.

**Conclusion:** Although our study needs a larger patient group and longer follow-up duration GKRS can be considered as a definitive treatment modality to any type of CCF, not adjuvant modality.

**Key Words:** Gamma knife radiosurgery, Carotid-Cavernous Fistula

MEMO



---

# Scientific Session III

## Epilepsy/Cranial Rhizopathy

---

좌장: 아주대 안영환, 울산대 홍석호

## **EC-1. Usefulness of Three-dimensional Image reconstruction in Identification of Neurovascular Relationships for Microvascular Decompression**

**Changik Lee, Byung-chul Son**

*Department of Neurosurgery, Seoul St. Mary's Hospital, College of Medicine,  
The Catholic University of Korea*

**Objective:** Precise identification of the neurovascular relationships is essential in pre-surgical planning of microvascular decompression (MVD) for hemifacial spasm (HFS) and trigeminal neuralgia (TN). Although preoperative identification of the offending vessels has been greatly improved by development of MR techniques, MRI shows only two-dimensional slice images of tomographic volumes and does not provide satisfactory overview of neurovascular structures to understand complex anatomy of posterior fossa. Overcoming this limitation, several methods of three-dimensional (3D) image reconstruction using various MR sequences were proposed. We report the usefulness of 3D image reconstruction using time of flight (TOF) and proton density driven equilibrium (PDDE) images in preoperative identification of complex neurovascular relationship. In addition, the significance of the venous structures in the surgical trajectory is stressed.

**Methods:** Surgical planning with 3D image reconstruction was performed in 7 patients with HFS and 4 patients with TN. Using 3D slicer (shareware software, Harvard University, USA), segmentation of the arterial structures was performed by threshold method with TOF images, segmentation of the brainstem, cranial nerve, and vein was done with PDDE. Nerves and vessels were well discriminated by designating different colors. The offending arteries identified by high-resolution MR 2D images and 3D image reconstruction were compared with intraoperative findings.

**Results:** The correspondence of the offending vessels identified by preoperative high-resolution MR 2D images was 72.7% and that of 3D image reconstruction using 3D slicer was 90.9%. 3D image reconstruction predicted the disturbance of operative field by superior petrosal vein in 4 out 11 patients and these findings were well corresponded with intraoperative view except one patient.

**Conclusion:** 3D images reconstruction using 3D slicer is regarded as more accurate method in preoperative identification of offending vessels and surgical planning than conventional high-resolution MR 2D images in MVD. 3D visualization of complex neurovascular relationship in posterior fossa is helpful for the pre-surgical planning of MVD.



## **EC-2. Re-appearance of Lateral Spread Response After Successful Microvascular Decompression in Patients with Hemifacial Spasm**

**Minsoo Kim<sup>1</sup>, Sang-Ku Park<sup>2</sup>, Seunghoon Lee<sup>3</sup>, Kwan Park<sup>2</sup>**

<sup>1</sup>*Department of Neurosurgery, Gangneung Asan Hospital, Gangneung;*

<sup>2</sup>*Department of Neurosurgery, Konkuk University Medical Center, Seoul;*

<sup>3</sup>*Department of Neurosurgery, Samsung Medical Center, Seoul, Korea*

**Objective:** Intraoperative disappearance of lateral spread response (LSR) in patients with hemifacial spasm (HFS) implies adequate decompression of facial nerve from the culprit vessel. Despite of studies focusing the correlation between the disappearance pattern of LSR and clinical outcome, there have not been a quantitative study focusing on the postoperative change of LSR. This study aims to identify the relation between postoperative change of LSR and clinical outcome.

**Methods:** Patients were analyzed in a retrospective fashion who underwent microvascular decompression for the treatment of HFS between 2016 and 2018 in a single center. LSR was recorded before surgery, before decompression of facial nerve during MVD (BEFORE-MVD), after decompression during MVD (AFTER-MVD), and one month after MVD (POST-1mo). A trained neurosurgeon reviewed the medical record and labeled the presence of LSR. Clinical outcome was recorded at one week, one month, and one year after surgery. Favorable outcome was defined as complete resolution of spasm or intermittent faint spasm. The correlation was analyzed between the pattern of LSR and clinical outcomes.

**Results:** Total 882 patients were included in the analysis. LSR was present in 758 (77.9%) at BEFORE-MVD. Presence or absence of LSR at BEFORE-MVD was not correlated with clinical outcomes. Among the 758 with LSR presence at BEFORE-MVD, 758 patients showed LSR absence at AFTER-MVD. Presence or absence of LSR at AFTER-MVD was not correlated with clinical outcomes. Among the 696 patients with LSR presence at BEFORE-MVD and LSR absence at AFTER-MVD, LSR was not observed at POST-1mo in 520 patients. However, LSR was re-appeared in 176 patients. Among 62 patients whose LSR was present in BEFORE-MVD and POST-MVD, LSR in 39 patients disappeared at POST-1mo. Patients whose LSR finding at POST-1mo was not identical to that of POST-MVD did not showed statistical difference in clinical outcomes.

**Conclusions:** Intraoperative LSR finding may change after surgery, which does not predict clinical outcome. LSR should be used in confirming adequate decompression of the facial nerve from the culprit vessel, not in predicting clinical outcomes.



## **EC-3. Involvement of the Vertebral Artery in Hemifacial Spasm: Clinical Features and Surgical Strategy**

**Hyukjun Kwon<sup>1</sup>, Seunghoon Lee<sup>1</sup>, Kwan Park<sup>2</sup>**

<sup>1</sup>*Department of Neurosurgery, Samsung Medical Center, Sungkyunkwan University School of Medicine, Seoul;*

<sup>2</sup>*Department of Neurosurgery, Konkuk University Medical Center, Seoul, Korea*

The vertebral artery (VA)-involved hemifacial spasm (HFS) has distinctive clinical features and performing microvascular decompression (MVD) is challenging. We described the clinical presentations of VA-involved HFS and the outcomes of MVD using the interposition method. Between January 2008 and March 2015, MVD was performed in 271 patients with VA-involved HFS. Demographic characteristics, preoperative severity, intraoperative findings, spasm-free outcome, and complications were retrospectively evaluated. A control group of 1500 consecutive patients with non-VA-involved HFS was enrolled.

VA-involved HFS was associated with older age ( $p < 0.001$ ), less female predominance ( $p < 0.001$ ), more left-sided predominance ( $p < 0.001$ ), and rapid symptom progression before MVD ( $p < 0.001$ ). The Teflon Fulcrum method allowed intraoperative identification of the neurovascular compression site in 92.6% of the cases, and showed more severe indentation on the facial nerve ( $p < 0.001$ ). Changes in the brainstem auditory evoked potentials during MVD ( $p < 0.001$ ) and postoperative non-serviceable hearing loss ( $p < 0.001$ ) were more frequent in patients with VA-involved than in non-VA-involved HFS. The spasm-free outcome and overall complication rates after MVD were not significantly different between the groups. VA-involved HFS has distinctive clinical features and poses a major surgical challenge for MVD success. The interposition method is a feasible surgical strategy in VA-involved HFS.

MEMO



## **EC-4. Pitfalls in SEEG Surgery**

**So Hee Park, In-ho Jung, Kyung Won Chang, Hyun Ho Jung,  
Jin Woo Chang, Won Seok Chang**

*Department of Neurosurgery, Brain Research Institute, Yonsei University College of Medicine,  
Seoul, Korea*

Epilepsy affects approximately 1% of the population, with 30-35% of patients having medically refractory epilepsy. Numerous noninvasive methods can be implemented to identify the epileptogenic zone (EZ). However, when noninvasive investigations are discordant or the EZ is adjacent to eloquent brain, invasive intracranial monitoring is necessary for more accurate and valuable diagnostic information that helps guide surgical decision-making. At the present time, the most common methods of invasive monitoring are stereo-electroencephalography (sEEG), subdural grid electrodes (SDG) and depth electrodes. The main advantages of sEEG monitoring are the ability to record from deep structures, the ability to record from the contralateral structure without craniotomy, and a low incidence of complications such as hematomas. We reported pitfalls in sEEG implantation surgery through our experience in a single institute.

MEMO



---

# **Symposium II**

## **Early Experience as a Young Functional Neurosurgeon**

---

좌장: 연세대 **장원석**, 인제대 **한성록**

**CURRICULUM VITAE**



**최진규**

근무처: 가톨릭대학교 의과대학 여의도성모병원 신경외과 임상조교수

E-mail: nschoi@catholic.ac.kr

**학력 사항**

- 2007            충남대학교 의과대학 의학학사
- 2019            가톨릭대학교 의과대학 의학박사

**경력 사항**

- 2007-2008     인턴, 강남성모병원/성빈센트병원
- 2008-2012     전공의, 서울성모병원 신경외과
- 2015-2016     임상강사, 서울성모병원 신경외과,
- 2017-2018     임상조교수, 서울성모병원 신경외과
- 2018-현재     임상조교수, 여의도성모병원 신경외과

**학회 활동**

- 대한정위기능신경외과학회 홍보이사
- 대한신경외과학회 홍보위원, 교과서편집위원회 간사
- 대한말초신경학회 전산정보이사
- 대한신경통증학회 학술간사
- 대한신경조절학회 이사
- 대한노인신경외과학회 치매인지장애연구회 간사
- 대한신경손상학회 이사





## 난치성 요실금과 변실금 치료를 위한 천수신경조절술

최진규

가톨릭대학교 여의도성모병원 신경외과

난치성 요실금과 변실금의 치료에 이용되고 있는 천수신경조절술(Sacral Neuromodulation, SNM)은 1982년에 Tanagho와 Schmidt에 의해 개발되고, 1997년에 FDA 승인을 받으면서 세계적으로 그 사용이 점차 증가하고 있다. 국내에서는 수술 건수가 2010년부터 점차 증가하여 2019년과 2020년 기준, 연간 50례 정도 시행되고 있으나, 신경조절술의 주요 주체인 신경외과에는 알려진 바가 거의 없다. 저자는 이번 학술대회의 '젊은 정위가능신경외과의사의 초기 경험' 세션을 통해 천수신경조절술의 적응증, 국내허가사항 및 급여 기준, 초기 경험을 통한 수술 방법과 환자 치료 과정 등에 대해 발표하고자 한다.

미국에서 천수신경조절술은 행동요법, 약물치료 보톡스 치료 등에 반응하지 않는 난치성 요실금, 잔뇨, 급박뇨, 빈뇨, 변실금에 사용되고 있으며, 캐나다와 유럽에서는 만성 변비에도 이용되고 있다.

국내 허가사항은 미국과 유사하다. 요실금의 경우 6개월 이상의 적절한 보존적 요법(약물요법과 행동치료 등)으로도 효과가 없는 절박성 요실금(urge incontinence), 빈뇨(urinary frequency), 비폐쇄성 요폐(non-obstruction urinary retention) 증상이 있는 경우에 시험적 거치술을 시행할 수 있으며, 시험적 거치술 전 요역동학검사 결과와 최소 3일 연속 작성된 배뇨일지가 필요하다. 약물 부작용이 심하여 약물요법을 시행할 수 없는 경우는 조기 시행이 가능하다. 영구자극기설치술은 시험적 거치술 후 최소 3일 이상 연속 배뇨일지를 작성하여 50% 이상의 효과가 있는 경우에 시행 가능하다.

변실금에서는 6개월 이상의 식이조절, 약물치료, 괄약근운동/바이오피드백 등으로도 효과가 없는 난치성 변실금(지난 3개월 동안 평균 주2회 이상의 변실금) 증상이 있는 경우에 시험적 거치술을 시행할 수 있으며, 시험적 거치술 전 실시한 항문초음파 검사와 항문내압 검사, 최소 1주 연속 작성된 배변일지가 필요하다. 영구자극기 설치술은 시험적 거치술 후 1주일간 배변일지를 작성하여 50%이상 효과가 있는 경우 가능하다. 수술은 복와위에서 시행하며 환자의 상태에 따라 전신마취 또는 부분마취로 할 수 있다. C-arm을 이용하여 환자의 제3 천골공(S3 foramen)에 약 60도 각도로 전극을 삽입하는데, 수술 전 pelvic bone CT를 통해 환자 천골공의 대략적인 각도를 확인하면 수술 시 수월하게 찾을 수 있다. Guide wire를 먼저 삽입하고



그것을 통해 시험적 전기자극을 하여 적절한 반응이 나오는지 관찰한다. S2에 들어간 경우 항문이 조이는 느낌("clamp" of anal sphincter), 하지 근육 수축(Leg/hip rotation, ankle plantar-flexion, contraction of calf) 등의 반응을 관찰할 수 있으나 감각 반응은 불분명하다. S4에 삽입된 경우에는 하지의 운동 반응이 없다. 수술의 타겟이 되는 S3에 guide wire가 삽입된 경우, 전기 자극을 통해 회음부의 벨로우즈 사인("bellows" of perineum)과 발가락(주로 엄지)의 굴전(toe sign)이 운동반응으로 나타나고, 부분마취로 수술을 하는 경우에는 직장과 성기부분에 당기는 듯한 감각반응을 확인할 수 있다. 이 수술은 양측이 아닌, 편측에 전극을 삽입한다. 저자는 양측 S3 천골공에 모두 guide-wire를 삽입하고, 전기 자극에 더 뚜렷한 반응을 보이는 곳에 전극을 삽입한다. 전극 삽입 후, 전극을 연장선과 연결하고, 선의 원위부는 피하 터널을 통해 가능한 먼 곳에서 피부 밖으로 빼낸다(externalization). 원위부 전극과 시험자극 장치를 연결하여 수 일간 시험자극을 하며, 환자 만족도가 높고 적절한 효과가 있는 경우에는 시험자극시 사용한 연장선을 제거하면서 반대측 둔부에 이식과발생기를 넣어 전극과 연결한다.

천수신경자극술은 그동안 몇몇 임상 시험을 통해 난치성 요실금과 변실금에서 시도해 볼 수 있는 안전하고 효과적인 치료로 알려져 있으나, 한국에서는 아직 생소한 치료 방법이다. 건강보험심사평가원 자료에 의하면, 2010년부터 2020년까지 국내에서 시험적 거치술 기준, 요실금 206례, 변실금 52례가 시행되었으며, 영구자극기 삽입술은 요실금 146례, 변실금 37례로, 치료에 50%이상 반응을 보이는 것을 치료 성공이라 정의할 때, 요실금에서 70.8%, 변실금에서 71.2%의 성공률을 나타냈다. 80% 이상이 대학병원에서, 약 10%는 개인병원/의원에서 약 10%는 종합병원에서 시행되고 있다. 임상과별로는 요실금은 비뇨기과, 변실금은 외과에서 대부분 수술을 하고 있으며, 신경외과에서 수술한 경우는 약 2%로 드물다. 적응증이 되는 질환은 비뇨기과, 외과의 영역이라고 볼 수 있지만, 척추의 해부학과 X-ray를 이용한 중재시술 및 전극과 이식과발생기 삽입술 등, 치료의 영역에서는 신경외과의 전문 영역이라고 볼 수 있다.

천수신경자극술의 치료 메커니즘은 아직 밝혀지지 않았다. 대부분의 임상 연구들이 세밀한 해부학적 구분 없이 주로 적응증과 그 결과에 초점이 맞춰져 있는데, 이것은 비뇨기과, 외과에서 주로 임상연구가 이루어져 왔기 때문이라고 본다. 향후 치료 메커니즘의 규명과, 결과 향상을 위하여, 천수와 말초/내장신경의 관계, 중추신경계와의 상호작용, 좌측과 우측의 차이, 최적의 전기 자극 프로그래밍 개발 등에서 전문가인 신경외과의 역할이 반드시 필요하다고 생각한다.

## MEMO



**CURRICULUM VITAE**

**Young Goo Kim, MD**



**ADDRESS:** Clinical Assistant Professor, Department of Neurosurgery,  
Ewha Womans University School of Medicine,  
Ewha Womans University Mokdong Hospital, Seoul, Korea  
E-mail: ygkim@ewha.ac.kr headkorea@naver.com

**EDUCATIONAL BACKGROUND:**

1999-2005      Kosin University College of Medicine, Busan, Korea  
2005-2006      Gospel Hospital, Kosin University College of Medicine: Rotating Internship  
2010-2014      Severance Hospital, Yonsei University College of Medicine: Four-year Residency  
2013-2018      Graduate School, Yonsei University College of Medicine; Master of Science (Medical Science)

**PROFESSIONAL BACKGROUND:**

2014-2016      Clinical Fellow of Stereotactic and Functional Neurosurgery, Department of Neurosurgery,  
Yonsei University College of Medicine  
2016-2018      Clinical Assistant Professor of Department of Neurosurgery, Dongguk University College  
of Medicine  
2018-2019      Assistant Professor of Department of Neurosurgery, Dongguk University College of Medicine  
2019-present      Clinical Assistant Professor of Department of Neurosurgery, Ewha Womans University  
School of Medicine

**ACADEMIC ACTIVITIES**

2014-present      Member of Korean Neurosurgical society  
2014-present      Member of Korean Society of Stereotactic Functional Neurosurgery



# Intrathecal baclofen for the treatment of spasticity

**Young Goo Kim, MD**

*Department of Neurosurgery, Ewha Womans University School of Medicine,  
Ewha Womans University Mokdong Hospital, Seoul, Korea*

Intrathecal Drug Delivery System (IDDS) is well established as an effective treatment of patients with chronic nonmalignant or malignant pain and a tool for the management of patients with severe spasticity. However, in this lecture, based on the author's experience with IDDS for spasticity treatment, the mechanism of spasticity and the overall contents of Intrathecal baclofen (ITB) will be reviewed.

Spasticity has been described as "a motor disorder characterized by a velocity-dependent increase in tonic stretch reflex with exaggerated tendon jerk, resulting from hyper-excitability of the stretch reflex as one component of the upper neuron syndrome."

ITB is currently the most effective therapeutic modality for the severe spasticity of both cerebral and spinal origin in adult and pediatric patients. Careful patient evaluation, selection, and maintained therapies are essential to a successful ITB.

Once a patient receives a baclofen pump, close monitoring is needed for dose adjustment and device related problems. Baclofen overdose and withdrawal by either system failure or human error can cause significant side effects and be life-threatening. Excellent understanding of the baclofen delivery system, programming, and dose effects are needed to evaluate any patient complaints. Future uses of intrathecal pump therapy include the use of other intrathecal drugs besides baclofen (or in combination with baclofen) and the effects of location of the catheter tip at various spinal levels.

MEMO



**CURRICULUM VITAE**

**Kyung Rae Cho, MD, PhD**

**ADDRESS:** Assistant Professor, Department of Neurosurgery,  
Konkuk University Medical Center, Seoul, Korea  
E-mail: medicasterz@gmail.com

**Education:**

2009 MD: Sungkyunkwan University School of Medicine  
2019 PhD, ABT: Sungkyunkwan University School of Medicine

**Professional Affiliations**

2014-2016 Clinical Fellow, Department of Neurosurgery, Samsung Medical Center  
2017-2020 Clinical Instructor, Department of Neurosurgery, Samsung Medical Center  
2020-present Assistant Professor, Department of Neurosurgery, Konkuk University Medical Center



## Neuromodulation for intractable headaches

**Kyung Rae Cho, MD, PhD**

*Department of Neurosurgery, Konkuk University Medical Center, Seoul, Korea*

Cluster headache (CH) is one of most severe headache one can experience. In 10-15% of CH change into chronic form and pain attack repeats without remission period. Recently, neuromodulation techniques such as occipital nerve stimulation (ONS) and deep brain stimulation (DBS) are used in treatment of CH.

Seventy-nine year old man had over 10 years of CH attack. He had good response of occipital nerve block thus implanted ONS. Lead was implanted bilaterally but one side removed due to infection. He is now following without pain attacks for 2 years.

Thirty-eight year old man had 10 years of headache aggravated in 5 years. He had ONS implantation but removed because of poor symptom control. He had Lt. ventral tegmental area DBS for CH. Symptoms were improved some but still complains about headache.

Use of neuromodulation for CH is increasing with more evidences. Young functional neurosurgeons should be interested in treatment for CH too.

MEMO



## CURRICULUM VITAE

### Young Cheol Na, MD

**ADDRESS:** Assistant Professor, Department of Neurosurgery,  
Catholic Kwandong University College of Medicine, International St. Mary's Hospital  
Incheon, Korea

#### Education

2005                    Yonsei University, College of Medicine MD.  
2021-Present        Yonsei University, College of Medicine, Postgraduate School (MSc./PhD. Candidate)

#### Carrier

2008-2009            Internship in Severance Hospital, Yonsei University  
2009-2013            Residency of Neurosurgery, Severance Hospital, Yonsei University  
2013-2015            Clinical Fellow of Stereotactic and Functional Neurosurgery, Department of Neurosurgery,  
Yonsei University College of Medicine  
2014                    Short Term Visit, Nihon University, Tokyo, Japan  
2015                    Assistant Professor, Department of Neurosurgery, Catholic Kwandong University College  
of Medicine, International St. Mary's Hospital

#### Academic Activity

2013-present        Regular Member of Korean Neurosurgical Society  
2013-present        Regular Member of Korean Stereotactic and Functional Neurosurgery



## 젊은 정위기능신경외과 의사의 기초 연구 수주 및 셋업

**Young Cheol Na, MD**

*Department of Neurosurgery, Catholic Kwandong University College of Medicine,  
International St. Mary's Hospital, Incheon, Korea*

MEMO





---

# Symposium III

## Integration of Functional Neurosurgery and Recent Technology

---

좌장: 울산대 전상용, 인제대 김해유

## CURRICULUM VITAE

### 김 민 수

근무처: 울산대학교 의과대학 강릉아산병원 신경외과 임상조교수

E-mail: kimminsoo@fastmail.com kimminsoo@gnah.co.kr

#### 학력 사항

2006 차의과학대학교 의학과 졸업  
2014-현재 연세대학교 대학원 의학과 신경외과학 석박사통합과정 재학 중

#### 경력 사항

2006-2010 차의과학대학교 분당차병원 신경외과 인턴, 레지던트  
2011-2013 공중보건기사  
2014 차의과학대학교 분당차병원 신경외과 전임의  
2015-2016 연세대학교 의과대학 신경외과학교실(정위기능) 임상연구 조교수  
2017 가톨릭대학교 의과대학 인천성모병원 신경외과 촉탁의  
2018 효산의료재단 안양샘병원 신경외과 의사  
2019-2020 성균관대학교 의과대학 삼성서울병원 신경외과(뇌종양) 임상강사  
2021-현재 울산대학교 의과대학 강릉아산병원 신경외과 임상조교수



## Machine learning in intraoperative neurophysiologic monitoring

김 민 수

울산대학교 의과대학 강릉아산병원 신경외과

Machine learning is a branch of artificial intelligence that allows computers to learn from large complex datasets without being explicitly programmed. Although machine learning is already widely manifest in our daily lives in various forms, the potential of machine learning has yet to find its way into mainstream medical research. The complex diagnostic and therapeutic modalities used in neurosurgery provide a vast amount of data that is suitable for machine learning models. This study overviews the machine-learning's potential to assist neurosurgical care especially in intraoperative neurophysiologic monitoring.

MEMO



## CURRICULUM VITAE

### Seunghoon Lee, MD, PhD

**ADDRESS:** Assistant Professor, Department of Neurosurgery,  
Samsung Medical Center, Sungkyunkwan University School of Medicine, Seoul, Korea  
E-mail: shben.lee@samsung.com

#### Education:

2006 MD. Sungkyunkwan University School of Medicine  
2012 MS. Neurosurgery, Sungkyunkwan University School of Medicine  
2021 PhD. Neurosurgery, Sungkyunkwan University School of Medicine

#### Professional Experience

2008-2012 Resident, Neurosurgery, Samsung Medical Center, Sungkyunkwan University School of Medicine  
2015-2018 Clinical Fellow, Functional Neurosurgery & Neuro-oncology, Samsung Medical Center, Sungkyunkwan University School of Medicine  
2018-2020 Clinical Assistant Professor, Samsung Medical Center, Sungkyunkwan University School of Medicine  
2020- Assistant Professor, Samsung Medical Center, Sungkyunkwan University School of Medicine



# Application of Stereotactic Surgical Robot Systems in Neurosurgery

**Seunghoon Lee, MD, PhD**

*Department of Neurosurgery, Samsung Medical Center, Sungkyunkwan University School of Medicine, Seoul, Korea*

Neurosurgery deals with the brain, which is an organ with the most delicate and high-order functions in the human body and has insufficient reserve for irreversible damage. Therefore, neurosurgical instruments require more precision and safety than those used in other medical fields. In particular, stereotactic functional neurosurgery aims to restore neurological functions without damaging normal structures, so it is the most prime-need field that requires the use of tools with the most advanced technology. Over the past several years, robotic systems have become popular and widespread from stereotactic and spinal instrumentation applications to endoscopic and endovascular applications. In Korea, two robotic systems were introduced and we started robot-assisted surgeries recently. Herein, an overview of the path to surgical robotics in neurosurgery and the limitation of current robotic system is provided. And initial experiences of robot-assisted functional neurosurgery are illustrated.

MEMO



---

# Scientific Session IV

## Pain/Others

---

좌장: 가천대 김은영, 고려대 김종현

## PO-1. Percutaneous Balloon Compression of the Trigeminal Ganglion in Post-herpetic Trigeminal Neuralgia: Outcome in Case Series of 8 Patients

Myung-Ki Lee, MD

*Department of Neurosurgery, On General Hospital, Busan, Korea*

**Objective:** Post-herpetic trigeminal neuralgia (TN) frequently result in intractable neuropathic pain, which has various forms of clinical expression. Percutaneous balloon compression (PBC) of the trigeminal ganglion have been known as an effective procedure for the treatment of idiopathic TN. Until now, however, PBC related to post-herpetic TN has not been reported in the world. This report was carried out to analyze the treatment results in 8 patients with medically intractable post-herpetic TN who underwent PBC.

**Methods:** The ballooning compression of a pear shape shape after injection of contrast material was inflated for 60 seconds in a brief period general anesthesia. Eight patients with follow-up of 1 year after surgery were retrospectively analyzed. There were 6 males and 2 females, ranging in age of onset from 43 to 83 years (mean, 70.4). The duration of disease at time of surgery was 4 months to 20 years (mean, 3.9). V1 division alone, V1 and V2, and V3 were affected in 5 patients, 1, and 2, respectively. The visual analogue scale (VAS) pain score, Barrow Neurological Institute (BNI) intensity score, and the common component elements of neuropathic pain were assessed at 1 year after surgery.

**Results:** The VAS scores were reduced from 8.0 before surgery to 4.8 after surgery. The BNI scores were reduced from BNI-4 to BNI-5 (8 cases) to BNI-3a (1), BNI-3B (3), and BNI-4 (4) after surgery. Intermittent electrical shooting pain and evoked pain with allodynia was marked improvement after surgery, but steady burning, dysesthetic pain was little improvement. The adverse effects were insignificant.

**Conclusions:** Medically intractable neuropathic pain with intermittent neuralgic pain and allodynia in patients with post-herpetic TN may benefit from PBC of the trigeminal ganglion.

MEMO



## **PO-2. Which stimulation Mode is Most Effective for Postplegic Neuropathic Pain in a Patient with Combined Vc DBS and Cervical SCS**

**Dong Wook Kim, Young Seok Park**

*Department of Neurosurgery, Chungbuk National University College of Medicine, Cheongju, Korea*

Deep brain stimulation provides a further opportunity to alleviate pain in central post-stroke pain, atypical facial pain, brachial plexus injury, and some patients who have failed SCS. We introduce pain modulation effect a patient who underwent combined bilateral Vc DBS and Cervical SCS after cervical cord injury.

A 59-year-old male patient suffered a cervical spine injury after a motor-vehicle accident 6 years ago. He underwent anterior cervical fusion surgery, and improve quadriparesis after surgery. However, he complained aggravating severe burning and neuropathic pain (VAS 10/10). He visited CBNUH in 2017 and performed SCS insertion. At first, the pain improved (VAS 4/10) after Cervical SCS. However the pain in both upper extremities continued especially it aggravated exposed the cold air. He complained of extreme cold and unusual sensations, even in midsummer, requiring him to wear a duck down jacket. The VAS score was 8-10 points. After that, he performed the IT morphine and IT baclofen tests, and there was no significant effect, and various side effects such as urinary retention and urticaria occurred. Exploratory bilateral Vc DBS insertion was performed because it was thought that the previous pain intervention effect was very limited. After surgery, the pain with a VAS score of 4 was reduced by 50-70%, oral medications were reduced, and quality of life was improved. We compared SCS and DBS stimulation effect in open test. Simultaneous DBS and SCS stimulation had the greatest pain reduction effect. Next was DBS. SCS alone was the least effective. Turning on the SCS had a greater pain reduction effect than turning it off. Although it is a case report, it can be said that in shows an synergistic DBS and SCS effect of reducing upper extremity pain after postplegic pain.

**MEMO**





## **PO-3. Compulsive Cuts of Neurosurgical Labor fee in MVD Surgery**

**Young Hwan Ahn**

*Department of Neurosurgery, Ajou University School of Medicine, Suwon, Korea*

We, neurosurgeons are constantly being forced to take on unlimited and infinite responsibility even in a low medical cost environment, and we are experiencing unfairly infringing on the treatment authority and right of neurosurgeons.

I briefly summarize a case whose TN and GPN were treated with a single MVD and an unreasonable notice of compulsive cut of neurosurgical labor fee. I hope this case is open to discussion.

**MEMO**



## **PO-4. Stereotactic Surgery using the Kymero Stereotactic Robotic Device**

**Kyung Won Chang, Jin Woo Chang**

*Department of Neurosurgery, Yonsei University College of Medicine, Seoul, Korea*

**Objective:** Stereotactic surgery is traditionally performed manually with the use of Stereotactic frame. However, currently many robotic devices are developed for stereotactic use. Modern robotic-assist surgical systems have changed the stereotaxic procedures by increasing operative efficiency while preserving and even improving accuracy and safety. Here we report the stereotactic surgery using Kymero stereotactic robotic device with 3 cases.

**Methods:** 3 cases using the kymero stereotactic robot device is described. The cases were stereotactic biopsy, Stereotactic electroencephalography (SEEG) placement, Stereotactic catheter placement.

**Results:** Procedures were as follows, Preoperative MRI were merged with the intraoperative CT scanned after the robotic stereotactic frame was placed. Trajectories were planned by using the Kymero software by the neurosurgeon. Using the planned trajectory, the robotic arm was positioned to the target area. Successful surgery was performed in each case with accurate target placement. Trajectory was easily planned with the Kymero Software and targeting multiple area with less time and effort using the stereotactic robot was possible. Intraoperative CT showed good accuracy with no complications encountered.

**Conclusion:** With the Stereotactic robotic device, accurate and safe surgery can be conducted. Efficient trajectory adjustments can be made in multiple target area with ease than the traditional stereotactic frame, The case demonstrates robotic stereotactic assistance viability as an alternative to traditional frame-based stereotactic surgery.

MEMO



# 허곤 학술상

좌장: 인제대 김무성

# An investigation of Thalamic Nuclei Volumes and the Intrinsic Thalamic Structural Network Based on Motor Subtype in Drug Naïve Patients with Parkinson's Disease

박진세, 박강민, 조근열, 이현곤, 최병삼, 신경진, 하삼열, 박성호, 이호준, 김해유

*Department of Neurosurgery, Haeundae Paik Hospital, Inje University College of Medicine, Busan, Korea*

**Introduction:** This study aimed to investigate the alterations in thalamic nuclei volumes and the intrinsic thalamic structural network in patients with de novo Parkinson's disease (PD) based on their predominant symptoms.

**Methods:** We enrolled 65 patients with de novo PD (44 patients with tremor-dominant [TD] subtype and 21 patients with postural instability and gait disturbance [PIGD] subtype) and 20 healthy controls. All subjects underwent three-dimensional T1-weighted magnetic resonance imaging. The thalamic nuclei were segmented using the FreeSurfer program.

**Results:** We obtained volumetric differences in the thalamic nuclei of each subtype of PD in comparison of healthy control. Volumes of the right and left suprageniculate nuclei were significantly increased, whereas that of the left parafascicular nucleus was decreased in patients with the TD subtype. Volumes of the right and left suprageniculate nuclei and right ventromedial nucleus were significantly increased, whereas those of the right and left parafascicular nuclei volumes were decreased in patients with the PIGD subtype. The measures of the intrinsic thalamic global network were not different between patients with TD PD and healthy controls. However, in patients with the PIGD subtype, the global and local efficiencies were significantly increased compared to healthy controls. Moreover, although there were no differences in thalamic volume and intrinsic thalamic global network between patients with the TD and PIGD variants, we identified significant differences in the intrinsic thalamic local network between the two groups.

**Conclusions:** Alterations in thalamic nuclei volumes and the intrinsic thalamic network in patients with PD differed based on their predominant symptoms. These findings might be related to the underlying pathogenesis and suggest that PD is a heterogeneous syndrome.



## **P-1. The Effect of Acute Exposure to RFR on Iba1-positive Microglia in Neonatal Rat Brain**

**Hye Sun Kim<sup>1,2</sup>, Hyung Do Choi<sup>3</sup>, Jeong-Ki Pack<sup>4</sup>, Nam Kim<sup>5</sup>, Young Hwan Ahn<sup>1,2</sup>**

*<sup>1</sup>Ajou University School of Medicine, Suwon; <sup>2</sup>Graduate School of Ajou University, Suwon; <sup>3</sup>Electronics and Telecommunications Research Institute, Daejeon; <sup>4</sup>Chungnam National University, Daejeon; <sup>5</sup>Chungbuk National University, Cheongju, Korea*

As the use of mobile technologies increases, exposure to radiofrequency electromagnetic radiation (RFR) continues to increase overtime. Development of early stage of central nervous system consists of axonal growth and synapse formation as well as the differentiation of stem cells into various immature CNS cells. During this stage, brain are known extremely sensitive to RFR exposure. Microglia are only activated under pathological conditions and interact dynamically with neurons. We studied the effect of RFR on Ionized calcium-binding adaptor protein-1 (iba1)-positive microglia in neonatal rats.

One-week-old Sprague Dawley rats (n=32) were divided into 4 groups as follows; cage-control, sham-exposed, 1.5 RFR exposed-, and 6.0 RFR exposed- groups (n=8 in each group). Rats in sham-exposed group were exposed to the whole body specific absorbed rate (wbSAR) of 0W/kg in the same chamber as the RF exposed-group. Rats in the 1.5 RFR exposed-group and 6.0 RFR exposed-group were exposed to an 848.5 MHz CDMA signal at 1.5 W/kg wbSAR for 45 min or at 6 W/kg wbSAR for 15 min. Brain samples were collected 3 days after completion of RFR exposure. To detect morphological changes, immunohistochemistry was performed using an Iba1 antibody and Iba1-positive microglia were manually counted. Western blotting was performed using Iba1 antibody to measure microglia activity.

There were no significant RFR-exposure induced changes in morphology and cell number of Iba1-positive cells. Iba1 protein level was increased in the 6.0 RFR exposed-rats compared to the other three groups. This study suggests that acute RFR exposure at 6 W/kg wbSAR likely induces microglia reactivity although morphological change or cell number change were not induced. Further studies are needed to evaluate the long-term effects of RFR exposure on microglial physiology.

This work was supported by the ICT R&D program of MSIT/IITP [2019-0-00102, A Study on Public Health and Safety in a Complex EMF Environment].



## P-2. Focused Ultrasound Mediated Temozolomid Delivery Into Intact Blood-brain Barrier Tissue Improves Survival of Patient Derived Xenograft Rat Model of Glioblastoma

Won Seok Chang<sup>1,2</sup>, Jaewoo Shin<sup>1,2</sup>, Jin-Kyoung Shim<sup>1,3</sup>, Chanho Kong<sup>1,2</sup>,  
Younghee Seo<sup>1,2</sup>, Seok-Gu Kang<sup>1,3</sup>, Jin Woo Chang<sup>1,2</sup>

<sup>1</sup>Department of Neurosurgery, Yonsei University College of Medicine, Seoul;

<sup>2</sup>Brain Research Institute & Brain Korea 21 PLUS for Medical Science, Yonsei University College of Medicine, Seoul;

<sup>3</sup>Brain Tumor Center, Severance Hospital, Yonsei University College of Medicine, Seoul, Korea

**Objective:** Glioblastoma (GBM) is the most common and aggressive type of primary brain tumor in adult, characterized by highly proliferative and infiltrative activity into the normal brain. Currently, GBM shows >80% of recurrences in the area adjacent to the resection site even after the maximal resection of tumor and temozolomide (TMZ) chemotherapy. The effectiveness of treatment is limited not only due to drug resistance but also due to restriction of passage due to the blood-brain barrier (BBB). In this study, we investigated the effect of FUS to transiently open BBB and optimal delivery time point of the TMZ to the human GBM infiltrated into the normal brain before tumor neo-vascularization in patient derived xenograft models (PDX).

**Methods:** PDX model was made by injecting human GBM tumorspheres (TSs; TS 15-88) into the striatum of male athymic nude mice (4-8 weeks). For the early stage of PDX model, TMZ was injected and FUS was applied to the striatum a week after GBM TSs implantation. BBB permeability was identified with Evans blue (EB) extravasation, MRI with gadolinium-enhanced T1-weighted image and tight junction protein of ZO-1 expression level, and infiltrated GBM TSs into brain tissue was confirmed by IHC of ZEB-1 staining and H&E staining in wild type, control PDX, and the FUS PDX group. To evaluate the therapeutic effect of combined treatment of GBM TSs with FUS and TMZ, bioluminescence and survival rate were analyzed.

**Results:** We confirmed that BBB permeability was not significantly different between wild type and PDX models. The FUS-induced BBB opening significantly increased EB extravasation and significantly reduced the expression levels of ZO-1. Bioluminescence imaging showed that the combination of FUS



and TMZ considerably reduced the proliferation of GBM TSs in PDX model. Combined treatment of GBM TSs with FUS and TMZ significantly increase in survival rate compared to the control and TMZ single treatment.

**Conclusions:** In the present study, we demonstrated that FUS with TMZ can enhance treatment effect more than standard chemotherapy in PDX model for therapy of GBM TSs before tumor neo-vascularization. This combined therapy has the potential to reduce recurrences and tumor growth and serve as a novel therapeutic protocol for the treatment of GBM patients.

Keywords: focused ultrasound, glioblastoma multiforme, blood-brain barrier, temozolomide

MEMO



## P-3. Brain-Machine Interface Based Analysis of Neural Signals in Somatosensory Cortex with Virtual Reward

Tae Jun Kim<sup>1</sup>, Yoon Kyung Cho<sup>3</sup>, Heesue Chang<sup>1</sup>, Chin Su Koh<sup>1</sup>, Minkyung Park<sup>1,2</sup>, Sang Beom Jun<sup>3</sup>, Hyun Ho Jung<sup>1</sup>, Jin Woo Chang<sup>1,2</sup>

<sup>1</sup>Department of Neurosurgery, Yonsei University College of Medicine, Seoul;

<sup>2</sup>Brain Korea 21 PLUS Project for Medical Science and Brain Research Institute, Yonsei University College of Medicine, Seoul; <sup>3</sup>Department of Electronic and Electrical Engineering, College of Engineering, Ewha Womans University, Seoul, Korea

Neural signal changes in the brain can be detected by Brain-Machine-Interface (BMI) technology in order to control external machines or computers. In this experiment, neural signals from the somatosensory area in rats were analyzed in real-time and used as a control signal for external device. Providing visual feedback followed by stimulation of medial forebrain bundle (MFB), which is the main area of virtual reward, enables the animal to learn how to control the mechanical unit, a cursor. This study implemented a design of BMI that can be controlled by visual feedback and analyze neural signals from somatosensory cortex in the absence of signals from motor cortex.

This study aims to extract signals from neurons and generate machine control cues through signal processing so experimental animals can perform various machine controls. Customized tungsten electrodes were implanted to provide virtual rewards in the MFB and two pair of screws were implanted at the surface of S1 barrel cortex of rats to obtain neural signals. For real-time processing, RHD2000 and Matlab was combined for experimental animals to control the machine through learning.

Motor cortex is the main brain area in conventional brain-machine interface studies. However, in this study, it was confirmed that a non-motor neural signal-based BMI is applicable through the independent movement of the left and right whiskers. It is also notable that rats can be fully trained by visual feedback with MFB stimulation and finally move the cursor to the target area.

This study showed the possibility that somatosensory cortex can be an effective alternative region for BMI when the motor region is impaired. It has been demonstrated that rats are able to move the cursor with stimulation-based visual feedback without any physical movements.

### Acknowledgement

This work was supported by the National Research Foundation of Korea (NRF) grant funded by the Korea government (MSIT) (2021R1I1A1A01047750 and 2020R1F1A1074104)





# 대한정위기능신경외과학회 회칙

## 제1장 총 칙

### 제1조 (명칭)

이회는 대한신경외과학회의 분과학회로(1990년에 창설된 대한신경외과학회의 대한뇌정위기능학술연구회를 모체로 하여 1991년에 설립되었으며), 대한정위기능신경외과학회(The Korean Society of Stereotactic and Functional Neurosurgery, 약칭 KSSFN)라 칭한다.

### 제2조 (목적)

이회는 대한신경외과학회의 학술연구회로서 정위기능신경외과학 분야의 임상 및 기초 연구를 통한(에 대한) 학문발전과 회원 상호간의 학술교류 및 친목을 도모하는데 그 목적이 있다.

### 제3조 (사업)

이회는 전조의 목적을 달성하기 위해 다음과 같은 사업을 한다.

1. 학술대회, 강연회 및 연수교육의 개최
2. 학술발전을 위한 계획 수립 및 사업시행
3. 정위기능신경외과학분야 학회지 및 도서 발간
4. 회원 상호간의 친목도모를 위한 사업 시행
5. 기타 이회의 목적 달성을 위한 제반사업 시행

## 제2장 회 원

### 제4조 (구성 회원 및 자격)

이회의 회원은 정회원, 종신회원, 준회원 그리고 특별회원으로 구분하며, 아래의 회원자격을 갖춘 자로 한다.

1. 정회원은 대한신경외과학회 정회원으로서 이회의 목적에 찬동하고 이의 달성을 위해 협력하는 자로 한다.  
(정회원은 대한민국의 의사면허증과 신경외과 전문의 자격증을 소지하고 학회의 취지에 찬동하여 소정의 입회수속을 밟고 상임이사회의 승인을 얻은 자가 된다.)
2. 종신회원은 정회원 중 정해진 액수의 종신회비를 납부하고 소정의 수속을 필한 자로 한다.
3. 준회원은 이회의 목적에 찬동하는 전공의나 그에 상응하는 자격을 갖춘 자로 한다. 상응하는 자격이라 함은 의사가 아닌 공학, 생물학, 기초의학자를 포함하며, 간호사, 방사선사 등 의료관련 자격자도 포함한다. 준회원은 피선거권과 투표권이 없다.
4. 특별회원은 이회의 목적에 찬동하고 발전에 기여할 수 있는 자로서 상임이사회의 승인을 얻은 자로 한다.



**제5조 (입회)**

1. 정회원의 입회는 제4조 1항의 자격을 갖추고, 이회에 소정의 회원 가입 신청서를 제출한 자를 회장, 총무 상임이사, 회원관리상임이사가 회원자격을 심의 후 지체 없이 승인 여부를 결정하여 당사자에게 통보하고, 상임이사회에 보고하여 이루어진다.
2. 학회 주관 행사에서 발표하고자 하는 자는 별도의 절차없이, 회원가입 신청 및 연회비 납부만으로 회원 가입이 가능하고, 그 자격은 결격 사유가 없는 한 유지 될 수 있다.

**제6조 (권리 및 의무)**

1. 회원은 이회의 회칙을 준수하여야 한다.
2. 회원은 이회에서 규정한 연회비 및 기타 부담금을 납부하여야 한다.
3. 정회원 중 세계학회(WSSFN) 회원 자격을 2015년에 획득한 자는 그 자격을 유지하기 위한 연회비의 일부를 납부하면, 세계학회 회원자격을 유지할 수 있는 학회의 지원을 받을 수 있다.
4. 종신회원은 종신회비를 납부하였으므로 연회비의 납부를 면한다.(단, 종신회원 중 WSSFN 회원의 자격을 유지하고자 하는 자는 그 자격을 유지하기 위한 연회비의 일부를 납부해야한다.)
5. 회원은 이회의 각종 행사에 적극적으로 참여하여야 하며, 이회의 회원으로서 품위를 유지해야 한다.
6. 이회의 의무를 다한 정회원은 선거권, 피선거권 및 각종 집회에서의 발의 및 의결권을 갖는다.

**제3장 임 원****제7조 (임원의 구성)**

이회는 다음의 임원을 둔다.

1. 회장 1명
2. 부회장 1명
3. 상임이사(학술, 총무, 재무, 간행, 교육, 전산 및 홍보, 보험, 회원관리, 회칙개정, 윤리, 국제교류, 젊은정 위기능신경외과모임 외) 약간 명
4. 운영위원 약간 명
5. 감사 2명
6. 전임회장단
7. 명예회장
8. 고문

**제8조(임원의 선출)**

1. 회장과 부회장은 상임이사회에서 선출하여 운영위원회 및 총회에서 인준을 받아야하며, 임기는 1년으로 하고 연임할 수 없다.
2. 감사는 총회에서 선출하고 임기는 2년으로 한다.
3. 전임회장은 당연직으로 전임회장단에 가입된다.



**제 9조 (명예회장)**

학회는 회장을 역임한 자 중에서 학회에 공로가 현저한 자를 상임이사회의 심의를 거친 후 총회에서 명예회장으로 추대할 수 있다.

**제 10조 (고문)**

학회는 학회에 공로가 현저한 자를 상임이사회의 심의를 거친 후 총회에서 고문으로 추대할 수 있다.

**제11조 (임원의 보선)**

회장 결위시에는 부회장이 회장의 업무를 대행하며, 부회장 결위시 상임운영위원회에서 잔여 임기동안의 부회장을 선출한다.

**제12조 (임원의 의무)**

1. 회장은 이회를 대표하고, 운영위원회, 상임운영위원회, 총회의 의장이 되며, 학술대회를 주관하고 이회의 운영에 관계되는 제반 사항을 지휘 감독한다.
2. 부회장은 당연직으로 차기회장이 되며, 회장 결위시 회장의 업무를 대행한다.
3. 이회의 상임이사는 종신회원 중에서 회장이 임명한다.
4. 총무이사는 상임이사 중 회장이 임명하며 이회의 제반 업무를 총괄 한다.
5. 감사는 이회의 회무 및 재정을 감사하고 그 결과를 총회에 보고한다.
6. 전임회장단은 학회 발전을 위해 자문하는 역할을 한다.

**제4장 회 의**

**제13조 (회의)**

이회의 회의는 정기총회, 임시총회, 상임이사회의, 운영위원회의, 젊은정위기능신경외과모임으로 구분한다. 정기총회는 정회원으로 구성되며, 매년 1회 정기학술대회 시 개최하고, 임시총회 및 기타 회의는 필요시 회장이 소집할 수 있다.

**제14조 (상임이사회의)**

상임이사회는 운영위원 중에서 구성되며, 의장은 회장이 된다. 위원 1/2이상의 출석으로 성립되고, 출석위원 과반수의 찬성으로 의결한다. 단, 위원이 사정상 회의에 참석하지 못할 때는 위임장이나, 이에 상응하는 의사표시로 위임할 수 있으며, 가부 동수일 경우에는 의장이 의결권을 가진다.

학술, 총무, 재무, 간행, 교육, 전산 및 홍보, 보험, 회원관리, 회칙개정, 윤리, 국제교류 등의 업무를 분담하고, 이회의 운영에 관한 중요사항을 의결한다. 전임 회장단은 투표권 없이 참석하여 자문할 수 있다.

**제15조 (운영위원회)**

운영위원회는 회장, 부회장, 상임이사, 운영위원으로 구성되고, 의장은 회장이 된다. 운영위원회는 위원 1/2



이상의 출석으로 성립되며, 출석위원 과반수의 찬성으로 의결한다. 단, 운영위원이 사정상 회의에 불참할 경우 위임장이나 이에 상응하는 의사표시로 위임할 수 있다.

운영위원회는 회장의 자문에 응하여 본회의 제반 활동에 관한 사항을 심의 의결한다. 운영위원은 회장이 수련 병원에 종사하는 정회원 중 상임이사회의 승인을 받아 선임한다.

#### 제16조 (젊은정위기능신경외과모임)

정위기능신경외과학회의 지속적인 발전을 위하여 만45세 이하 정회원으로 구성된 젊은정위기능신경외과 모임을 만들고, 학술활동 및 교류를 증대시킨다. 이 모임은 원활한 업무를 위해 모임의 장과 총무를 선출하고, 이는 상임이사회에서 인준한다.

### 제5장 회 계

#### 제17조 (자산 및 회계)

1. 학회의 자산은 회비(연회비, 종신회비), 정기학술대회 등록비, 찬조금 및 기타 수익금으로 하며, 회장의 책임 하에 관리 운용한다.
2. 학회의 사업 연도는 매년 학술대회 및 정기총회 종료 후 차기 총회까지로 한다.
3. 각 연도의 수입, 지출, 결산은 감사의 심사를 거쳐 총회에 보고한다.

### 제6장 회칙 개정

#### 제18조 (회칙개정)

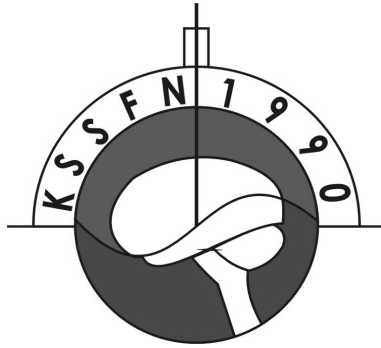
이회의 회칙은 상임이사회에서 상임이사의 재적인원 2/3 이상이 참석하고, 출석위원 2/3 이상의 찬성으로 개정할 수 있으며, 총회에서 출석정회원 2/3 이상의 가결로 인준을 받는다.

#### 제7장 부 칙

1. 이회의 회칙에 규정되지 아니한 사항은 민법의 규정 또는 일반관례에서 준용한다.
2. 회칙은 인증된 날로부터 실시한다.
3. 개정된 회칙은 총회 인증 후 당해 연도 총회 이후 실시한다.
4. 이 회칙은 2000년 2월 11일 1차 개정하였다.
5. 이 회칙은 2002년 3월 8일 2차 개정하였다.
6. 이 회칙은 2007년 3월 16일 3차 개정하였다.
7. 이 회칙은 2010년 3월 27일 4차 개정하였다.
8. 이 회칙은 2015년 3월 28일 5차 개정하였다.
9. 이 회칙은 2017년 3월 25일 6차 개정하였다.
10. 이 회칙은 2018년 3월 31일 7차 개정하였다.

이 회칙은 대한의학회의 인준을 받은 날부터 시행한다.





## 2021 대한정위기능신경외과학회 제 26차 정기 학술대회 및 총회

---

발행인: 김 무 성

편집인: 손 병 철 · 이 태 규

발행처: **대한정위기능신경외과학회**

경기도 의정부시 천보로 271

가톨릭대학교 의정부성모병원 신경외과

전화: 031-820-3070 팩스: 031-847-8077

---

인쇄처: 도서출판 **의학출판사**

서울특별시 중구 을지로 14길 15

전화: 02-713-2446 팩스: 02-2279-3960

발행일: 2021년 10월 1일

---